



The Comparison of Ketokonazol and Hypochlorous Acid (HOCl) Applications for the Treatment of The Fungal Infections (Dermatophytosis)

Mahmut Babur^{1,a}, Başaran Karademir^{2,b,*}

¹District Directorate of Agriculture and Forestry Ministry, Doğubayazıt /Ağrı, Türkiye

²Iğdır University, Faculty of Applied Sciences, Iğdır, Türkiye

*Corresponding author

ARTICLE INFO

ABSTRACT

Research Article

Received : 19-01-2023

Accepted : 16-03-2023

Keywords:

Fungi
Therapy
HOCl
Cat
Dog

Dermatophytosis is a mycotic disease of the skin that is resistant to treatment. The aim of this study was to investigate the treatment efficacy of a novel antimicrobial agent, Hypochlorous Acid (HOCL), on dermatophytosis of cats and dogs, in comparison with Ketaconazole. In this study, a total of 76 animals (26 cats and 50 dogs) without any disease other than skin fungal infection after clinical, hematological, biochemical, microscopic and Wood's lamp examinations were used. Subjects were randomly assigned to two equal treatment groups within their own species as HOCL: HP and Ketaconazole: KT. Naked eye inspection results were collected on the 8th, 11th and 15th days of all patients. The study was terminated on the 15th day by collecting the Wood's lamp and microscopic examination data together with the last inspection finding. Findings were analyzed statistically with chi-square and CART (Classification and Regression Tree) algorithm test. Inspection results of the treatment groups exhibited significant recovery over time (day 8, 11 and 15) for both species ($P < 0.05$). However, the 15th day Wood's lamp and microscopic examination did not confirm the inspection findings. It was seen that the gender did not affect the results ($P > 0.05$). According to the microscopic examination results, a significant statistical difference was observed between the HP and KT groups ($P < 0.05$), but the same situation were not seen on the inspection and Wood's lamp examinations ($P > 0.05$). As a result, it was concluded that HOCl has an effect on dermatophytosis of cat and dogs, although not as much as Ketaconazole, but further studies are needed to reveal the results more clearly.

^a mahmudbabur@gmail.com

^{ib} <https://orcid.org/0000-0003-4519-300>

^b basaran_k@hotmail.com

^{ib} <https://orcid.org/0000-0002-6604-9021>



This work is licensed under Creative Commons Attribution 4.0 International License

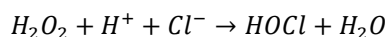
Introduction

Dermatophytosis is a zoonotic fungal disease localized to the epidermis layer of the skin, hairs and nails in many animal species as well as in humans. *Micosporum* (especially *M. canis*), *Trichophyton* and *Epidermophyton spp.* are the main agents of the disease (Yapici et al., 2017; Wisal, 2018; Hanedan et al., 2021). Dermatophytosis is also called by different names such as fungus, ringworm, trichophytosis, *Candidia* and *Yeast*, depending on its localization on the organism, host type or similar condition (Şimay, 2014). Although it is located far from impact area of the organism's defense systems, the inefficacy of the immune and other defense systems plays an important role in the arise of the disease (Lagowski et al., 2019). Besides, the humidity rate of the region, the deterioration of the keratinized tissue in the epidermis layer of the skin, zinc, vitamin A and D deficiencies are also important factors in the arise of the cases (Al-Janabi and Bashi, 2018; Çifci, 2018).

Although dermatopytosis appears as a simple superficial disease on the skin, it is quite resistant to treatment. (Sánchez et al., 2014; Şimay and Karademir, 2015; Indarjulianto et al., 2020). Therefore, it can be treated with long and expensive treatment processes (Katirae et al., 2021). Therefore, the search of alternative treatment options gain importance.

Hypochlorous Acid (HOCl) is a novel antimicrobial agent that has incoming in the field of human and animal health (Wang et al., 2007; Ateş, 2020). Basically, HOCl is produced by nicotinamide and adenine dinucleotide phosphate oxidase in the mitochondria of phagocytic cells in the defense system and ensures that the phagocytized microorganisms are inactivated by breaking their DNA (Ateş, 2020). First, hydrogen peroxide is formed from oxygen and water in the mitochondrial membrane, then Hypochlorous Acid is formed in accordance with the

following chemical reaction equation, catalyzed by myeloperoxidase (Wang et al., 2007).



Synthetically, it is reported that HOCl is formed by acidification of hypochlorite, electrolysis of salt solution, reverse reaction of sodium hypochlorite and hydrogen peroxide, and hydrolysis of chlorine gas (Wang et al., 2007; Sakarya et al., 2014). After administration, HOCl entering the organism is neutralized by taurine produced by the brain and liver and converted to Chloramine (Kearns and Dawson, 2002). After external applications, HOCl becomes unstable after contact with water, air or exposure to sun rays and loses its effect. (Rutala et al., 1998; Ishihara et al., 2017).

In the daily life using areas of the HOCl are personal care and cleaning, environmental cleaning, etc. (Goto, 2015; Ateş, 2020). As for the usage areas in health services superficial skin infections, acute and chronic wound, antiseptics of the operation site before and after the operation, mastitis, metritis, rhinitis, sinusitis, ocular and oral lesions, skin burns can be exemplify (Hakim et al., 2015; Gray et al., 2016; Karabulut and Gülay, 2016; Fuentes, 2018; Kim and Nam, 2018; Kanclerz et al., 2019; Block and Rowan, 2020; Fam et al., 2020; Gold et al., 2020; Joachim, 2020).

There are also some reports related to HOCl and fungal disease; It has been reported that HOCl causes deformation on fungal agent via destroying cellular electron transport chains and the adenine nucleotide pool (in vitro) (Albrich et al., 1981; Aratani et al., 2000; Odorcic et al., 2015; Romanowski et al., 2020). Again, Romanowski (2020) reported that they obtained successful feedback from the use of HOCl as a disinfectant against bacteria, yeast and viruses in the use of contact lenses.

On the other hand, it is also reported that there is an increase in fungal and bacterial activities in the environment in case of disruption of the immune system's own endogenous HOCl production in the respiratory system (Aratani et al., 2000).

In this study, it was aimed to investigate the therapeutic efficacy of HOCl on feline and canine dermatophytosis with external use, in comparison with Ketoconazole, which has proven its efficacy before.

Material and Methods

Animal Material and Ethics

The subjects of this study were selected from among the cats and dogs submitted to the animal shelter affiliated to the Dogubayazit Municipality Veterinary Affairs Directorate for routine control, examination and treatment. First of all, the animals were subjected to routine clinical examinations. After the physical examination, anticoagulant and non-anticoagulant blood samples were taken, and hematological and biochemical tests required for routine examination were performed. After all examinations, 26 cats (15 males, 11 females) and 50 dogs (14 males and 36 females) aged 1-5 years without any health problems other than dermatophytosis were included in this study (76 subjects in total).

All manipulations on the animals used in this study were performed only within the framework of clinical examinations in accordance with the Experimental Animal Ethical Legislation (Anonymous, 2009).

Formation of Groups and Drug Administration Program

After the diagnosis of dermatophytosis was confirmed by clinical, Wood's lamp and microscopic examinations, 15 male and 11 female cats were randomly divided into two groups of 13 individuals as 8 males, 5 females, 7 males and 6 females. 50 dogs (14 males and 36 females) were randomly divided into two groups of 25 as 7 males and 18 females. Random treatment groups were assigned to the randomly selected cat and dog groups; (1) Hypochlorous Acid (HOCl) (Crystalin spray®, Crystalin): HP group and (2) Ketoconazole (Ketoral pomade® 2%, Bilim): KT group. After shaving and cleaning the area with dermatophytosis lesion, HOCl as spray and Ketoconazole as pomade were externally applied over the whole area twice a day (10:00-22:00) for 14 days.

Laboratory Facilities

After routine clinical examinations, Medonik brand M32 model blood count device was used for hematological examinations, and "Beckman Coulter" brand, "AU400" model Autoanalyzer device was used for biochemical examinations. Skin scrapings taken from dermatophytosis lesions were used for microscopic examinations. Scrapings, treated with 10% KOH, were examined by microscopy equipped with objectives 10 and 40 (Kelly, 1984).

Wood's light is obtained after the light beam from high pressure mercury lamps passes through a barium silicate filter with 9% nickel oxide (320-400 nm). Aromatic amino acids, collagen, elastin, melanin precursors and their products, which are not normally found in the skin but appear in deformations in the skin in cases such as dermatophytosis, cannot be seen with the naked eye, but they cause fluorescent reflections under Wood's light (bright yellow-green, blue-green) (Sav, 2017; Moriello, 2019; Türkmen and Türkoğlu, 2019). In the research, "Archer" brand Wood's lamp was used as Wood's light source.

Statistical Analysis

Chi-square test was applied for statistical comparison of numerical values of recovery status of treatment groups (Tabachnick and Fidell, 2013; Kara, 2020).

$$X^2 = \sum_{i=1}^n \frac{(OF-EF)^2}{EF}$$

- OF : Observed frequency
- EF : Expected frequency
- X² : Chi-Square test result
- n : Subject number
- n-1 : Degree of Freedom

For each treatment group, Friedman test was applied to reveal the effect of time on the recovery numbers detected on the 8th, 11th and 15th days of the inspective examination.

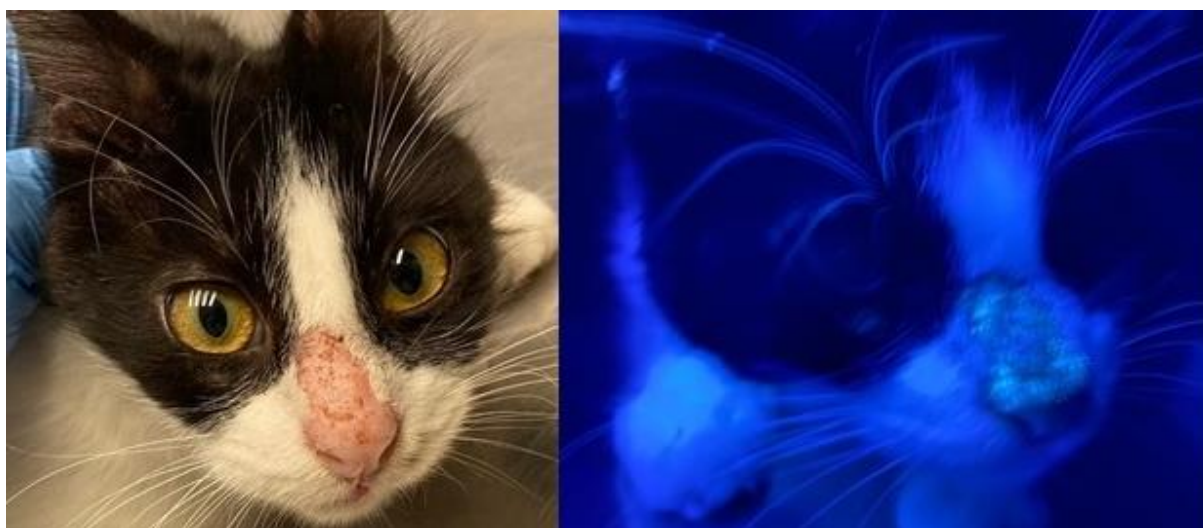

Figure 1. The appearance of a dermatophytosis lesion on Wood's light examination

PC analysis is a method that reveals the relationship between groups in all aspects (Salvatore et al., 2016; Kulak et al., 2020). In the present study, the PC analysis method was employed to reveal the relationships between the recovery findings according to the treatment groups and examination methods in all aspects. The operating system used for PC analysis was the Past 3.26 software program (Hammer et al., 2001).

Classification and Regression Tree (CART) is a non-parametric and advanced data mining algorithm that is relatively simple to interpret even for non-statisticians (Lemon et al., 2003; García et al., 2019) (Nisbet et al., 2009). In this study, CART analysis was used to reliably interpret the improvement in treatment groups according to diagnostic methods (Inspection, Wood's lamp and Microscopic).

Results and Discussion

Secondary infection or other pathologies are probably to cause confusion in the diagnosis of dermatophytosis or in obtaining treatment outcomes (Al-Khalidi et al., 2011; Tan and Knight, 2018; Nguyen and Ichiki, 2019). Unless dermatophytosis is a very extreme situation, it does not cause a change in clinical, hematological and biochemical findings. On the other hand, many systemic infections or other pathologies easily cause changes in these parameters (Kelly, 1984; Karademir, 2001; Nelson and Couto, 2019). For this reason, in order to eliminate the presence of another secondary pathologies in all cats and dogs included in the study, subjects having normal values for these parameters were included in the study (Taşçene and Karagül, 2008; Lee et al., 2019; Alkan et al., 2020; Blazizza et al., 2021) (Table 1).

There are many scientific studies reporting that species, race and sex factors may be effective in cases of dermatophytosis among animal species or vice versa (Yokoi et al., 2010; Neves et al., 2018; Siğirci et al., 2019; Łagowski et al., 2019; Hanedan et al., 2021; Katirae et al., 2021). Nonetheless, in the presented study, the results obtained when the post-treatment findings are handled separately for cats and dogs are seen in Table 2 and no statistical difference was observed between the data of the species ($P>0.05$). No statistical difference was observed in terms of recovery numbers between gender groups

($P>0.05$) within each treatment group, as it was between species. For this reason, in order to make a clearer assessment, the results of the two species were considered together and statistical analyzes were made on the total data.

The first finding obtained since the beginning of the study is the inspection finding. In the study, recovery signs of dermatophytosis began to be observed approximately from the 8th day. Then gradually the signs of improvement continued to progress. According to the inspection data on the 15th day, a complete recovery was observed in the KT group, although not in the HP group. Based on this time, the study was terminated. The improvement results of the treatment groups over time were analyzed by Friedman statistical method. Friedman test results, as follows; for group HP; n: 38, Chi-Square Value: 45.6, df: 2, Significance: $P<0.001$, and for Group KT; n: 38, Chi-Square Value: 21.1, df: 2, Significance: $P<0.001$. According to these results, statistically significant recovery was detected in both treatment groups over time. The recovery status of both treatment groups is clearly illustrated in Figure 2. These results indicate that HOCI may also be an effective agent, similar to the results of different anti-mycotic trials on dermatophytosis (Ertaş et al., 2015; Odorcic et al., 2015; Wisal, 2018; Choi et al., 2019; Endo et al., 2020; Indarjulianto et al., 2020; Romanowski et al., 2020; Brescini et al., 2021).

Although the improvement level in the HP group was not as much as the KT group in the inspective examination findings, the data on the 15th day showed a high rate of recovery for both groups, and therefore, no statistical difference was observed between the inspection data of the treatment groups ($P<0.05$). However, recovery rates in Wood's light and microscopic examination findings were far from inspection findings (Table 3). According to Wood's lamp findings, the difference between the recovery levels of the treatment groups was low, so no statistical difference could be detected between them. However, the data obtained from the microscopic examination findings differed slightly from the data obtained from the Wood's lamp method. In the microscopic method, a higher recovery rate was observed in the KT treatment group compared to the Wood's lamp data, while the recovery rate was lower in the HP group. The difference between the treatment groups was also statistically significant ($P<0.001$) (Table 3).

Table 1. Clinical, Hematological and Biochemical examination results

	Cat	Dog
Clinical Findings		
Respiration (pcs/min)	29.69±5,23	27.86±4,26
Pulsation (pcs/min)	121.54±23,44	113.98±19,15
Temperature (°C)	38.65±0.39	38.12±0.42
Dehydration (%)	0±0	0±0
Hematological Findings		
Htc (%)	40.98±5,89	44.13±4.60
Hgb (g/dL)	12.20±1,68	15.27±1.28
RBC (million pcs/mm ³)	7.65±1,58	6.17±0.80
WBC (thousand pcs/mm ³)	10.42±3,76	12.55±2.57
MCV (µm ³)	45.92±2,59	67.77±3,46
MCH (pg)	15.35±1.41	22,38±2,02
MCHC (g/dL)	33.10±1,19	35.79±1,47
Biochemical Findings		
CK (U/L)	85.00±18,87	69,70±21,19
ALT (U/L)	55.35±18,73	34,40±8,77
AST (U/L)	31.42±13,20	26,48±5,93
ALP (U/L)	51.62±19,24	53,64±15,41
GGT (U/L)	5.35±1,72	6,76±1,77
Glucose (mg/dL)	92.35±.15,05	98,10±7,02
Urea (mg/dL)	24.26±4,71	22,02±4,97
Creatinine (mg/dL)	1.25±0.26	1.00±0.26

Table 2. Recovery number and rates of treatment groups according to examination methods (Inspection, Wood’s lamp and Microscopic) and subject species (cat and dog) on the last examination time

Groups	Subject Number	Inspective examination	Wood’s light examination	Microscopic examination
		Recovery number and rate	Recovery number and rate	Recovery number and rate
HP (Cat)	13	11 (84.62%)	7 (53.85%)	6 (46.15%)
HP (Dog)	25	23 (92%)	11 (44%)	10 (40%)
KT (Cat)	13	13 (100%)	8 (61.54%)	10 (76.92%)
KT (Dog)	25	25 (100%)	15 (60%)	18 (72%)

There was no statistical difference between cat and dog species for each treatment group.

Table 3. Statistical comparisons for the recovery numbers of treatment groups according to examination methods (Inspection, Wood’s lamp and Microscopic)

Groups	Total Subject	Inspective examination	Wood’s light examination	Microscopic examination
		Recovery number and rate	Recovery number and rate	Recovery number and rate
HP	38	34 (89.47%)	18 (47.37%)	16 (40.11%) *
KT	38	38 (100%)	23 (60.53%)	28 (77.78%)

There was no statistical difference between treatment groups for each examination method except Microscopic examination (*) (Chi-Square Test Value: 7.773, Degrees of Freedom: 1, P value: 0.005)

Ketoconazole treatment was expected to work well in light of previous scientific study reports (Endo et al., 2020; Moriello, 2020; Brescini et al., 2021; Anikar et al., 2022). However, the treatment rates observed in the HP group were not far below the KT group data. However, Wood’s light and Microscopic examination results were found to be quite low compared to the results of the inspective examination. This situation was inconsistent with the results of previous scientific studies on ketoconazole. The findings of this study revealed that the duration of treatment is not sufficient for a complete recovery. Whereas, the prospectus descriptions of the commercial preparation (Ketoral®) suggested that treatment could be terminated only a few days after the disappearance of clinical signs. The findings of this study revealed that the treatment outcome should be confirmed by Wood’s light

and/or microscopic examination to terminate the treatment (Sav, 2017; Moriello, 2019; Türkmen and Türkoğlu, 2019).

In the present study, PC analysis was performed to reveal the interrelationships of the effects of all groups on recovery findings, together with their vectorial aspect and strength (Hammer et al., 2001; Salvatore et al., 2016; Kulak et al., 2020) (Figure 3). Eigenvalues values and variance rates detected confirmed the reliability of PC analysis findings. PC 1 as the main component accounted for 95.65% of the total variation, while the secondary component PC 2 accounted for the remaining 4.35% of the total variation. According to PC 1, there was a positive correlation between the KT treatment group and the Microscopic examination findings, and between the HP treatment group and Wood’s lamp examination findings in terms of recovery findings, while these two main groups showed a negative correlation with each other.

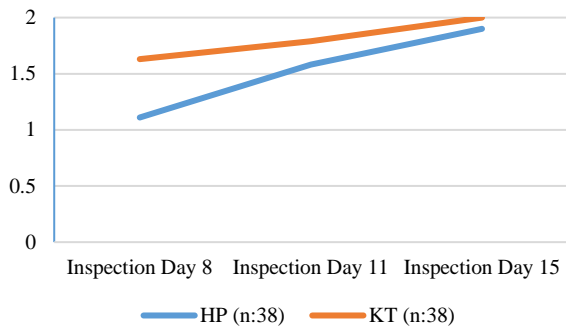


Figure 2. Recovery status of the treatment groups (HP and KT) according to the inspection findings on the 8th, 11th and 15th days.

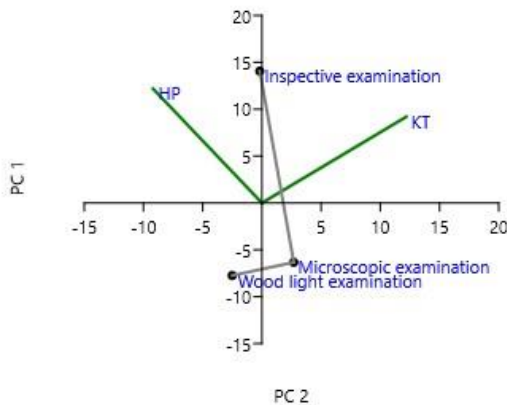


Figure 3. Principal Components (PC) analysis results for treatment groups and healing status according to examination methods (Inspection, Wood's lamp and Microscopic PC 1; Eigenvalue: 148.895, Variance: 95.65%, PC 2; Eigenvalue: 6.77213 Variance: % 4.35, PC 2: X, PC 1: Y

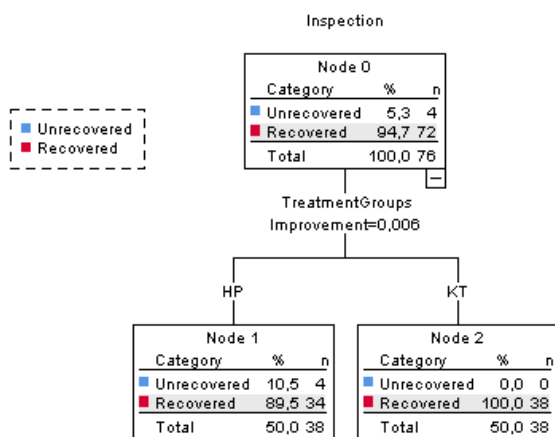


Figure 4. Evaluation chart of the inspection results on the 15th day according to the Decision tree algorithm (Model summary: Growing method: CRAT, Dependent variable: Inspection examination findings, Independent variables: Treatment groups HP and KT, Validation: Cross validation, Risk: Resubstitution-0.053, Cross-Validation-0.053, Classification: 94.7%)

According to PC 2, mainly, a negative correlation was detected between the inspective examination findings and both Wood's lamp and microscopic examination findings. Afterwards, as an important indicator, while both treatment groups showed a strong positive correlation with the inspection findings, showed a strong negative correlation with both Wood's lamp and microscopic examination findings. If the PS analysis results were evaluated together with clinical observations, it was concluded that the microscopic examination indicated a more accurate result than the Wood's lamp examination. The presented PS analysis results were in full agreement with and supported all other findings of the study (Figure 3).

The decision tree method CART algorithm is a statistical analysis method that increases the clarity of the collected data and facilitates its interpretation (Lemon et al., 2003; García et al., 2019). The CART analysis findings supported the previous findings of the study and visually detailed the details of the results as reported in previous studies (Figure 4-6). In case of looking to the sum of both treatment groups for inspection findings, 76 of the remaining 80 subjects, except 4, show recovery. Although the HP treatment group slightly decreased the recovery rate, this level is a rather high recovery rate. In Wood's lamp data, the total recovery rate is observed to be remarkably low with 53.9% (Figure 5). This level is even lower than the microscopic examination findings (Figure 6).

Wood's light is obtained by passing the light beam from high pressure mercury lamps through a barium silicate filter with 9% nickel oxide (320-400 nm). Formations capable of giving fluorescence, which are invisible in daylight, become visible under Wood's light. In natural conditions, aromatic amino acids, collagen, elastin, melanin precursors and products in the skin content fluoresce in this way (Sav, 2017; Moriello, 2019; Türkmen and Türkoğlu, 2019). It is reported that Wood's light is used in the diagnosis of dermatophytosis with an accuracy rate of 91% (Moriello, 2020). In another paper, it is reported that in cases of dermatophytosis, false negative results can be obtained in 20% of cats and 5.8% in dogs for Wood's lamp examination results (Moriello, 2004). On the other hand, it is reported that the Microscopic examination method prepared with skin scraping treated with 10% KOH is a rather reliable diagnostic method in the diagnosis of dermatophytosis (Mattei et al., 2014; Şimay, 2014; Şimay and Karademir, 2020). In the circumstances, one of the possible reasons for the difference between the recovery rates stated for the examination methods exhibited in Figures 5 and 6 can be considered as the emphasized margin of error. Additionally, it is also reported that some dermatitis conditions other than dermatophytosis give similar findings in Wood's lamp examinations (Leite and Renato, 2022)

The present study also has some limitations, such as; (1) It could have been better if different doses of HOCl and routes of administration had been used for this investigation, (2) again, the larger number of subjects in the groups could have been better in terms of the reliability of the results, (3) It is also known that dermatophytosis is a treatment-resistant skin disease. Recovery rates were likely to be greater in the case of a longer-term study. However, in this case, it could also lead to a misleading treatment group comparison. Thus, the prolonged treatment time

would have resulted in improvement in both treatment groups, leaving no opportunity for comparison in the end of the study. However, no information was found about the duration of the effect of HOCl on dermatophytosis and the ideal number of subjects for the groups. As explained above, we are of the opinion that this study will shed light on further studies in the treatment of dermatophytosis by means of HOCl.

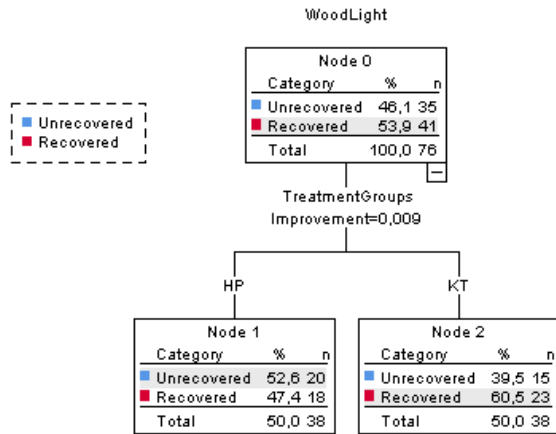


Figure 5. Evaluation chart of the Wood's Light examination results on the 15th day according to the Decision tree algorithm (Model summary: Growing method: CRAT, Dependent variable: Wood's Light examination findings, Independent variables: Treatment groups HP and KT, Validation: Cross validation, Risk: Resubstitution-0.434, Cross-Validation- 0.487, Classification: 56.6%)

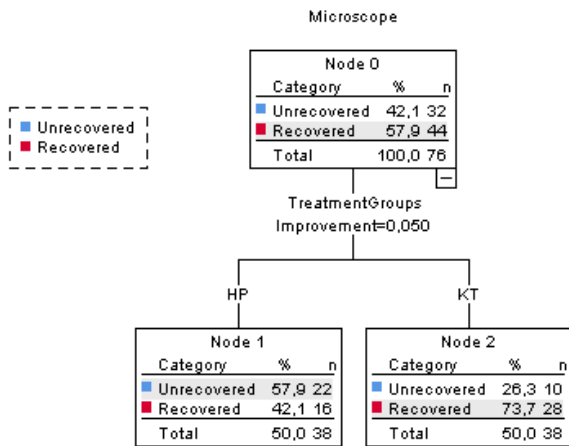


Figure 6. Evaluation chart of the Microscopic examination results on the 15th day according to the Decision tree algorithm (Model summary: Growing method: CRAT, Dependent variable: Microscopic examination findings, Independent variables: Treatment groups HP and KT, Validation: Cross validation, Risk: Resubstitution-0.324, Cross-Validation- 0.324, Classification: 65.8%)

Conclusion

Although a high level of recovery was observed in the inspective examination for both groups in the final stages of the study, the Wood's lamp examination and microscopic examination findings indicated that the study

period was not sufficient for a complete recovery for both groups. For this reason, improvement detected in dermatophytosis lesions according to the inspection findings showed that for an effective treatment result, it should be confirmed by Wood's lamp and, better still, microscopic examination. In the final comparison, it was observed that Ketaconazole treatment was more effective than HOCl treatment, especially according to the results of microscopic examination. However, signs of improvement were also detected in HOCl treatment, although not as clear as Ketaconazole. For this reason, it was concluded that HOCl may be an alternative treatment method for dermatophytosis and that the effectiveness of HOCl on the treatment of dermatophytosis should be investigated in more detail with further researches.

Conflict Of Interest Statement

The authors declare no conflicts of interest.

Acknowledgements

The authors would like to thank to Assoc.Prof. Evren KOÇ and Asist. Prof. Belkıs MUCA YİĞİT for valuable contributions

Information

This article was summarized from Mahmut BABUR's Master's thesis of the same name, and also presented as an oral presentation at the International European Conference on Interdisciplinary Scientific Research-VI, August 26-27, 2022, Bucharest, Romania.

References

- Albrich JM, McCarthy CA, Hurst JK. 1981. Biological reactivity of hypochlorous acid: implications for microbicidal mechanisms of leukocyte myeloperoxidase. *Proceedings of the National Academy of Sciences* 78: 210–214.
- Al-Janabi AAHS, Bashi AM. 2018. Development of a new synthetic xerogel nanoparticles of silver and zinc oxide against causative agents of dermatophytoses. *The Journal of Dermatological Treatment* 30: 283–287.
- Alkan KK, Çiftçi MF, Yeşilkaya ÖF, Satılmış F, Tekindal MA, Alkan H. 2020. Pyometralı köpeklerde laktat dehidrogenaz, tam kan ve bazı serum biyokimya parametreleri arasındaki ilişkinin değerlendirilmesi. *Eurasian Journal of Veterinary Sciences* 36: 204–213.
- AL-Khalidi F Q., Saatchi R, Burke D, Elphick H, Tan S. 2011. Respiration rate monitoring methods: A review. *Pediatric Pulmonology* 46: 523–529.
- Anikar MJ, Bhadesiya CM, Gajjar PJ, Patel VA, Dadawala AI, Makwana PP, Patil DB. 2022. Evaluation of therapeutic protocols containing different antifungal agents to treat dermatophytosis in dogs. *The Pharma Innovation Journal* 11: 83–87.
- Anonymous (Anonim). 2009. T.C. Çevre ve Orman Bakanlığı, Doğa Koruma ve Milli Parklar Genel Müdürlüğü Tarih: 25.06.2009, sayı:159/5316.
- Aratani Y, Kura F, Watanabe H, Akagawa H, Takano Y, Suzuki K, Maeda N, Koyama H. 2000. Differential host susceptibility to pulmonary infections with bacteria and fungi in mice deficient in myeloperoxidase. *The Journal of Infectious Diseases* 182: 1276–1279.

- Ateş FM. 2020. Water, salt, hypochlorous acid and infection protection. Bayburt Üniversitesi Fen Bilimleri Dergisi 3: 154–160.
- Blazizza MFS, Rahal SC, Santos IFC, Silva BM, Ferreira GM, Oba E, Tsunemi MH, Takahira RK. 2021. Effects of a single session of whole-body vibration exercise on haematological and biochemical parameters, and serum cortisol levels in cats. *Comparative Exercise Physiology* 17: 1–6.
- Block MS, Rowan BG. 2020. Hypochlorous acid: A review. *Journal of Oral and Maxillofacial Surgery* 78: 1461–1466.
- Brescini L, Fioriti S, Morroni G, Barchiesi F. 2021. Antifungal combinations in Dermatophytes. *Journal of Fungi* 7: 727.
- Choi FD, Juhasz ML, Mesinkovska NA. 2019. Topical ketoconazole: a systematic review of current dermatological applications and future developments. *Journal of Dermatological Treatment* 30: 760–771.
- Çifci N. 2018. Retrospective evaluation of effects of vitamin D levels on skin diseases. *Kocaeli Medical Journal* 7: 47–54.
- Endo EH, Makimori RY, Companhia MVP, Ueda-Nakamura T, Nakamura CV, Dias Filho BP. 2020. Ketoconazole-loaded poly-(lactic acid) nanoparticles: Characterization and improvement of antifungal efficacy in vitro against *Candida* and dermatophytes. *Journal de Mycologie Médicale* 30: 101003.
- Ertaş R, Kartal D, Utaş S. 2015. Çocuklarda yüzeysel mantar enfeksiyonlarının klinik değerlendirilmesi. *Turkish Journal of Dermatology* 9: 186–189.
- Fam A, Finger PT, Tomar AS, Garg G, Chin KJ. 2020. Hypochlorous acid antiseptic washout improves patient comfort after intravitreal injection: A patient reported outcomes study. *Indian Journal of Ophthalmology* 68: 2439–2444.
- Fuentes L. 2018. Efecto del ácido hipocloroso como alternativa terapéutica sobre la endometritis bovina posparto. Universidad Técnica Ambato. Ciencias Agropecuarias, Tesis Medicina Veterinaria. Bachelor's Thesis. 2018. Ambato - Ecuador.
- García VJ, Márquez CO, Isenhardt TM, Rodríguez M, Crespo SD, Cifuentes AG. 2019. Evaluating the conservation state of the páramo ecosystem: An object-based image analysis and CART algorithm approach for central Ecuador. *Heliyon* 5: e02701.
- Gold MH, Andriessen A, Bhatia AC, Bitter Jr P, Chilukuri S, Cohen JL, Robb CW. 2020. Topical stabilized hypochlorous acid: The future gold standard for wound care and scar management in dermatologic and plastic surgery procedures. *Journal of cosmetic dermatology* 19: 270–277.
- Goto K. 2015. Use of hypochlorous acid solution as a disinfectant in laboratory animal facilities. *Annals of Clinical and Medical Microbiology* 1: 1005.
- Gray D, Foster K, Cruz A, Kane G, Toomey M, Bay C, Kardos P, Ostovar GA. 2016. Universal decolonization with hypochlorous solution in a burn intensive care unit in a tertiary care community hospital. *American Journal of Infection Control* 44: 1044–1046.
- Hakim H, Thammakarn C, Suguro A, Ishida Y, Nakajima K, Kitazawa M, Takehara K. 2015. Aerosol disinfection capacity of slightly acidic hypochlorous acid water towards newcastle disease virus in the air: an in vivo experiment. *Avian Diseases* 59: 486–491.
- Hammer O, Harper D, Ryan P. 2001. PAST: Paleontological Statistics software package for education and data analysis. Past 3.26 Oyvind Hammer, *Palaeontologia Electronica* 4(1): 9pp.
- Hanedan B, Bilgili A, Uysal MH. 2021. Kedi ve Köpeklerde deri mantar enfeksiyonlarının insanlarda oluşturduğu sağlık riskleri, kontrol ve sağaltım seçenekleri. *Icontech International Journal* 5: 10–17.
- Indarjulianto S, Yanuartono Y, Nururrozi A, Raharjo S, Ajiguna JC. 2020. Combination of systemic and topical treatment for feline dermatophytosis: A case report. *Acta Veterinaria Indonesiana* 8: 18–23.
- Ishihara M, Murakami K, Fukuda K, Nakamura S, Kuwabara M, Hattori H, Fujita M, Kiyosawa T, Yokoe H. 2017. Stability of weakly acidic hypochlorous acid solution with microbicidal activity. *Biocontrol Science* 22: 223–227.
- Joachim D. 2020. Wound cleansing: Benefits of hypochlorous acid. *Journal of Wound Care* 29: S4–S8.
- Kanclerz P, Grzybowski A, Olszewski B. 2019. Low efficacy of hypochlorous acid solution compared to povidone-iodine in cataract surgery antiseptics. *The Open Ophthalmology Journal* 13: 29–33.
- Kara T. 2020. Parametrik olmayan istatistik yöntemleri ders notları. Fen-Edebiyat Fakültesi İstatistik Bölümü: Yıldız Teknik Üniversitesi, İstanbul.
- Karabulut H, Gülay MŞ. 2016. Antioksidanlar. *MAE Vet Fak Derg* 1: 65–76.
- Karademir B. 2001. KAÜ Veteriner Fakültesi İç Hastalıkları Kliniklerine 1999 yılında kabul edilen hayvanların genel durumları. *Journal of Faculty of Veterinary Medicine, Istanbul University* 27: 377–383.
- Katirae F, Kosari YK, Soltani M, Shokri H, Minooieanhighi MH. 2021. Molecular identification and antifungal susceptibility patterns of dermatophytes isolated from companion animals with clinical symptoms of dermatophytosis. *Journal of Veterinary Research* 65: 175–182.
- Kearns S, Dawson R. 2000. Cytoprotective effect of taurine against hypochlorous acid toxicity to PC12 cells. *Advances in Experimental Medicine and Biology* 483: 563–570.
- Kelly W. 1984. *Veterinary Clinical Diagnosis*. Baillière Tindal, London.
- Kim Y-R, Nam S-H. 2018. Comparison of the preventive effects of slightly acidic HOCl mouthwash and CHX mouthwash for oral diseases. *Biomedical Research* 29: 1718–23.
- Kulak M, Gul F, Sekeroglu N. 2020. Changes in growth parameter and essential oil composition of sage (*Salvia officinalis* L.) leaves in response to various salt stresses. *Industrial Crops and Products* 145: 112078.
- Łagowski D, Gnat S, Nowakiewicz A, Osińska M, Zięba P. 2019. The prevalence of symptomatic dermatophytoses in dogs and cats and the pathomechanism of dermatophyte infections. *Postępy Mikrobiologii - Advancements of Microbiology* 58: 165–176.
- Lee SH, Kim JW, Lee BC, Oh HJ. 2019. Age-specific variations in hematological and biochemical parameters in middle- and large-sized of dogs. *Journal of Veterinary Science* 21: e7.
- Leite LL, Renato MB. 2022. Erythematous Plaque on the Groin and Buttocks. *Cutis* 109: E21–E23.
- Lemon SC, Roy J, Clark MA, Friedmann PD, Rakowski W. 2003. Classification and regression tree analysis in public health: Methodological review and comparison with logistic regression. *Annals of Behavioral Medicine* 26: 172–181.
- Mattei AS, Beber MA, Madrid IM. 2014. Dermatophytosis in small animals. *SOJ Microbiology & Infectious Diseases* 2: 1–6.
- Moriello K. 2019. Dermatophytosis in cats and dogs: A practical guide to diagnosis and treatment. *In Practice* 41: 138–147.
- Moriello KA. 2004. Treatment of dermatophytosis in dogs and cats: review of published studies. *Veterinary Dermatology* 15: 99–107.
- Moriello KA. 2020. Dermatophytosis. In: Noli C, Colombo S (eds), *Feline Dermatology*. Cham: Springer International Publishing, London, UK. pp 265–296.
- Nelson RW, Couto CG. 2019. *Small Animal Internal Medicine - E-Book* (6th Edition edn). Elsevier Health Sciences.

- Neves JJA, Paulino AO, Vieira RG, Nishida EK, Coutinho SDA. 2018. The presence of dermatophytes in infected pets and their household environment. *Arquivo Brasileiro de Medicina Veterinária e Zootecnia* 70: 1747–1753.
- Nguyen T-V, Ichiki M. 2019. MEMS-Based Sensor for Simultaneous Measurement of Pulse Wave and Respiration Rate. *Sensors* 19: 4942.
- Odorcic S, Haas W, Gilmore MS, Dohlman CH. 2015. Fungal Infections Following Boston Type 1 Keratoprosthesis Implantation: Literature Review and In Vitro Antifungal Activity of Hypochlorous Acid. *Cornea* 34: 1599–1605.
- Romanowski EG, Yates KA, Romanowski JE, Mammen A, Dhaliwal DK, Jhanji V, Shanks RM, Kowalski RP. 2020. The Disinfection of Bacterial, Fungal, and Viral Contaminated Contact Lenses and Cases with Hypochlorous Acid. *Investigative Ophthalmology & Visual Science* 61: 413–413.
- Rutala WA, Cole EC, Thomann CA, Weber DJ. 1998. Stability and bactericidal activity of chlorine solutions. *Infection Control & Hospital Epidemiology* 19: 323–327.
- Sakarya S, Gunay N, Karakulak M, Ozturk B, Ertugrul B. 2014. Hypochlorous acid: an ideal wound care agent with powerful microbicidal, antibiofilm, and wound healing potency. *Wounds* 26: 342–350.
- Salvatore S, Bramness JG, Roislien J. 2016. Exploring functional data analysis and wavelet principal component analysis on ecstasy (MDMA) wastewater data. *BMC Medical Research Methodology* 16: 81.
- Sánchez TAC, García PAE, Zamora CIL, Martínez MA, Valencia VP, Orozco AL. 2014. Use of propolis for topical treatment of dermatophytosis in dog. *Open Journal of Veterinary Medicine* 4: 239.
- Sav H 2017. Deri Hastalıklarında Mikolojik Tetkikler. *Dermatoz* 8: 1–6.
- Şiğirci BD, Metiner K, Çelik B, Kahraman BB, İkiz S, Bağcıgil A funda, Özgür N yakut, Ak S. 2019. Dermatophytes Isolated From Dogs and Cats Suspected Dermatophytoses in Istanbul, Turkey Within A 15-Year-Period: An Updated Report. *Kocatepe Veterinary Journal* 12: 116–121.
- Şimay T. 2014. Trikofitili sığırlarda trikofitozisin yaygınlığına göre serum çinko düzeyinin değerlendirilmesi. Yüksek Lisans Tezi. Kafkas Üniversitesi, Sağlık Bilimleri Enstitüsü, Veteriner İç Hastalıkları Anabilim Dalı. Kars.
- Şimay T, Karademir B. 2015. Trikofitili Sığırlarda Trikofitozisin Yaygınlığına Göre Serum Çinko Düzeyinin Değerlendirilmesi. 11. Veteriner İç Hastalıkları Kongresi, 21-23 Mayıs, sf: 106, Samsun-Türkiye.
- Şimay T, Karademir B. 2020. Evaluation of Serum Zinc Levels in Cattle with Trichophytosis According to Extensiveness of Trichophytosis. *Turkish Journal of Agriculture-Food Science and Technology* 8: 2416–2420.
- Tabachnick BG, Fidell LS. 2013. Using multivariate statistics (Sixty edn). Pearson Inc. Boston.
- Tan CL, Knight ZA. 2018. Regulation of Body Temperature by the Nervous System. *Neuron* 98: 31–48.
- Taşçene N, Karagül H. 2008. Diyabetli köpeklerde kan HbA1C düzeyleri. *Ankara Üniversitesi Veteriner Fakültesi Dergisi* 55: 75–78.
- Türkmen D, Türkoğlu G. 2019. Erythrasma frequency in patients with interdigital maceration. *Turkderm-Turk Arch Dermatol Venereology* 53: 97–100.
- Wang L, Bassiri M, Najafi R, Najafi K, Yang J, Khosrovi B, Hwong W, Barati E, Belisle B, Celeri C. 2007. Hypochlorous Acid as a Potential Wound Care Agent. *Journal of Burns and Wounds* 6: e5.
- Wisal G. 2018. An over view of canine dermatophytosis. *South Asian Journal of Research in Microbiology* 2: 1–16.
- Yapıcıer Ö, Şababoğlu E, Öztürk D, Pehlivanoglu F, Kaya M, Türütoğlu H. 2017. Kedi ve Köpeklerden Dermatofitlerin İzolasyonu. *Veterinary Journal of Mehmet Akif Ersoy University* 2: 125–130.
- Yokoi S, Sekiguchi M, Kano R, Kobayashi T. 2010. Dermatophytosis caused by *Trichophyton rubrum* infection in a dog. *Japanese Journal of Veterinary Dermatology* 16: 211–215.